

Sgrinio Cyn Geni Cymru
Antenatal Screening Wales



GIG
CYMRU
NHS
WALES

Iechyd Cyhoeddus
Cymru
Public Health
Wales

Ultrasound Observations Pathways: isolated echogenic bowel, isolated renal pelvis dilatation and isolated ventriculomegaly 2021

Version 3

Following extensive consultation the following ultrasound findings (markers, observations) are the only ones that should be routinely reported on the fetal anomaly ultrasound scan in Wales from 1st August 2018.

This document contains the pathways for care for women found to have a baby with one of these findings and replaces the previous booklet 'Specific ultrasound findings, guidelines for health professionals in Wales, 2015'.

Summary of Changes			
Date	Change	Page	Comments
May 2021	Isolated Echogenic Bowel Pathway	11	Pathway updated to include the offer of referral to fetal medicine for all women found to have isolated echogenic bowel at the fetal anomaly ultrasound scan.

Isolated Ventriculomegaly

This pathway is for women where only ventriculomegaly is identified on scan in the absence of any other identified structural abnormality (isolated).

Definition

Mild ventriculomegaly is when the ventricular atrial diameter, at any gestation measures 10.1mm to 12.0mm. A measurement of the cerebral ventricle(s) of 12.1mm to 15.0mm is classed as moderate ventriculomegaly. A measurement of 15.1mm and above is classified as hydrocephalus and should be treated as an abnormality and Antenatal Screening Wales standard US25 should be followed.

Any measurement of the ventricle(s) over 10mm will require follow up by a fetal medicine consultant.

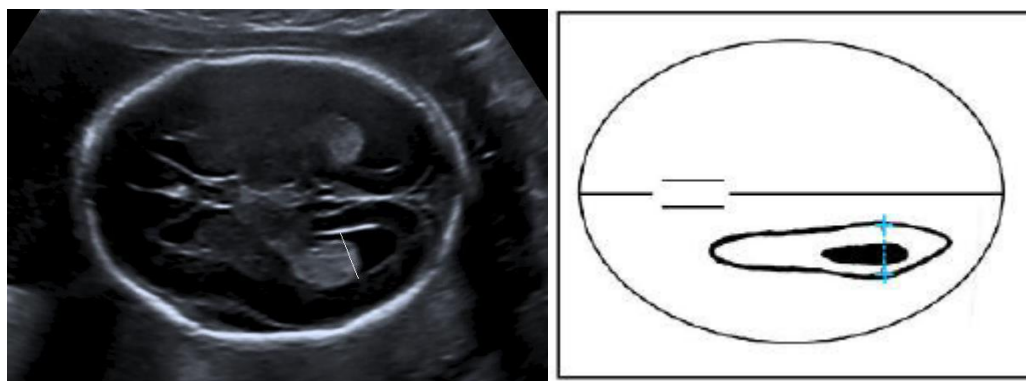
Possible Associated Clinical Conditions

- Congenital infections – rubella, toxoplasmosis and cytomegalovirus
- Neural tube defects
- Chromosomal or genetic conditions
- Abnormal cerebral development

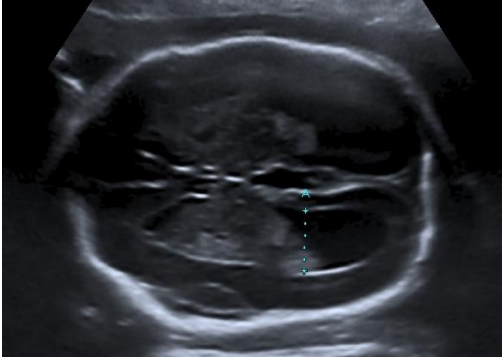Measurement

The correct plane for measurement of the ventricles requires the midline of fetal brain to be the midline of the image. The measurement at the atrium of the lateral ventricles should be taken at the level of the glomus of the choroid plexus bisecting the long axis of the ventricle. The callipers are placed to the inner margins of the echogenic ventricular wall 90° to the long axis of the ventricle.

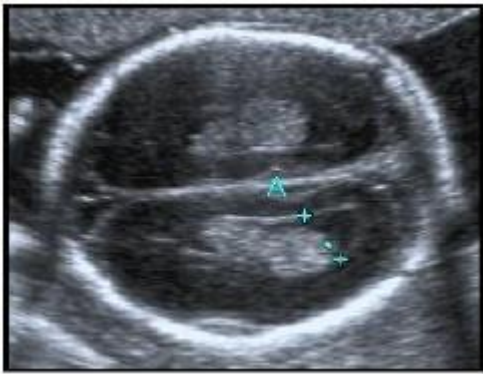
Normal ventricles showing correct measurement



Example of ventriculomegaly measurement



Example of incorrect measurement



The callipers are not placed at 90° to the long axis of the ventricle and the plane is incorrect.

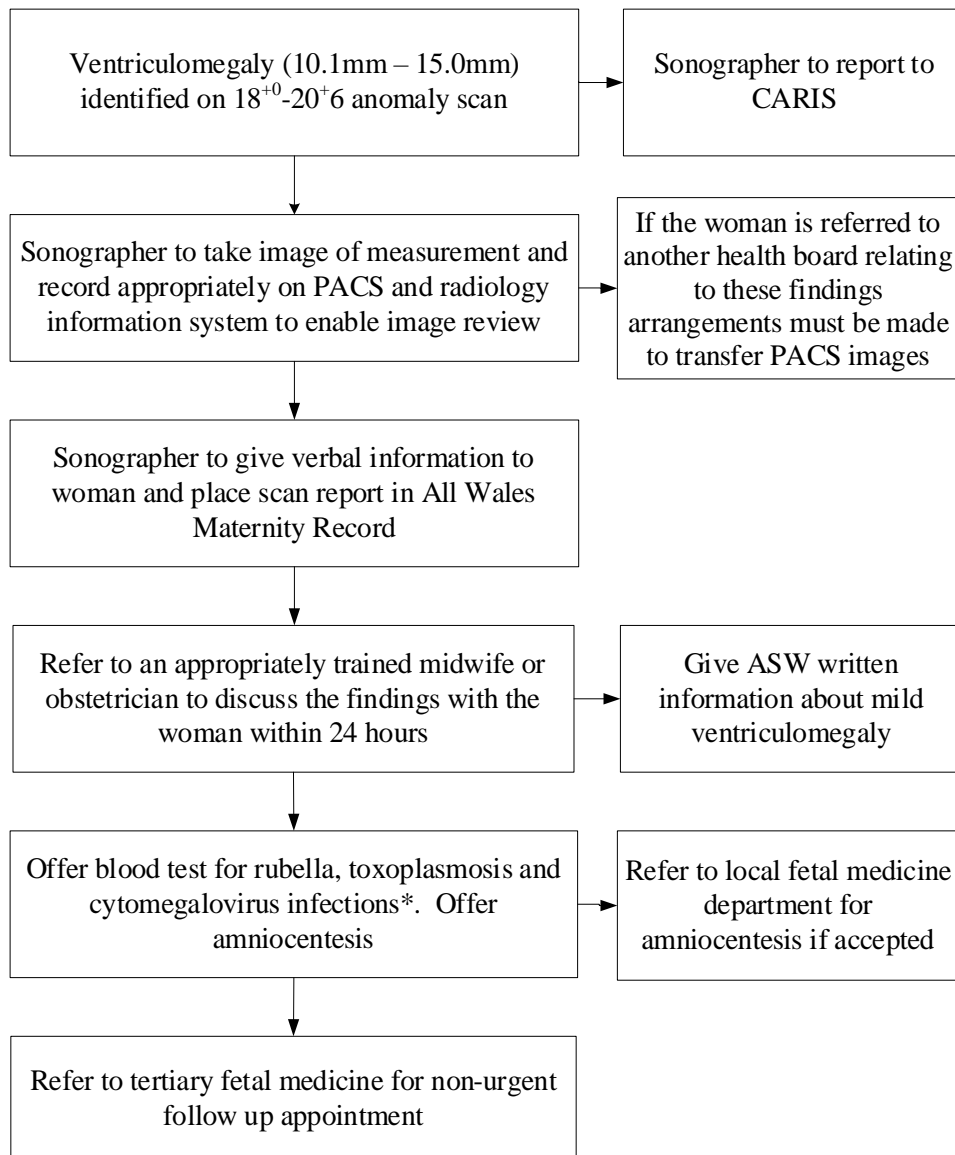
Quality Assurance

There must be an image from the fetal anomaly ultrasound scan stored for review by the obstetrician or fetal medicine consultant. If the woman is referred to another health board relating to these findings the arrangements must be made for image transfer via PACS.

An audit of images should be arranged by the Health Board Ultrasound Obstetric Lead as recommended by the Society and College of Radiographers and the British Medical Ultrasound Society¹.

¹ SCoR and BMUS (2020) "Guidelines for Professional Ultrasound Practice" 5th ed. Society and College of Radiographers and British Medical Ultrasound Society.

Pathway ventriculomegaly



* A current sample for these infections should be taken and the laboratory should be asked to compare result with booking blood if any stored.

Isolated Renal Pelvis Dilatation

This pathway is for women where only renal pelvis dilatation is identified on scan in the absence of any other identified structural abnormality (isolated).

Definition

If the anterior–posterior (AP) diameter of the fetal renal pelvis measures 5.1mm or more this is known as renal pelvis dilatation (RPD). If the RPD measures 10.1mm or more the woman should be referred to an obstetrician for further discussion and follow-up, if the RPD measures 15.1mm or more the woman should be referred to a fetal medicine department.

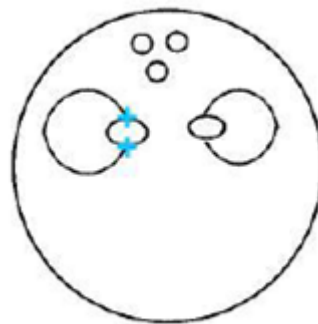
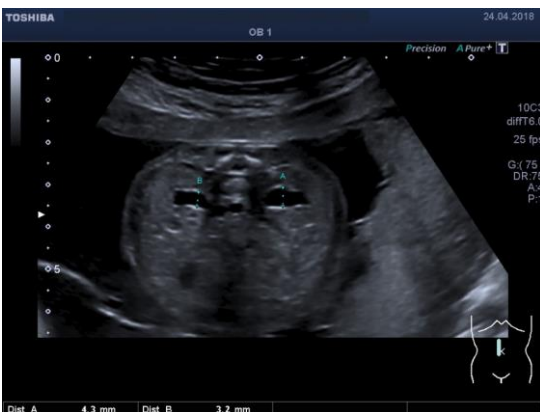Possible Associated Clinical Conditions

- Renal infections
- Abnormalities in the renal tract occasionally require postnatal surgery

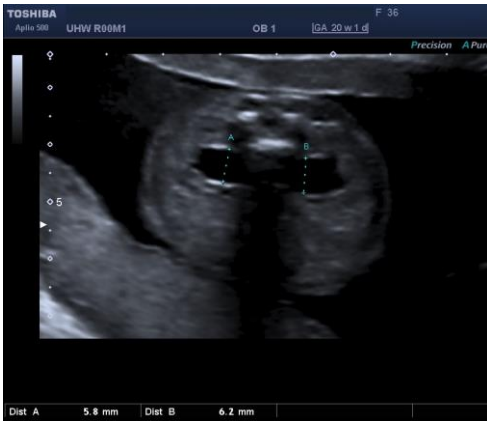Measurement

Fluid filled dilatation of the renal pelvis measured on axial section with an AP diameter of 5.1mm or more (callipers to be placed on the inner AP margins of the renal pelvis wall) measured at the level of the kidneys. This may be unilateral or bilateral.

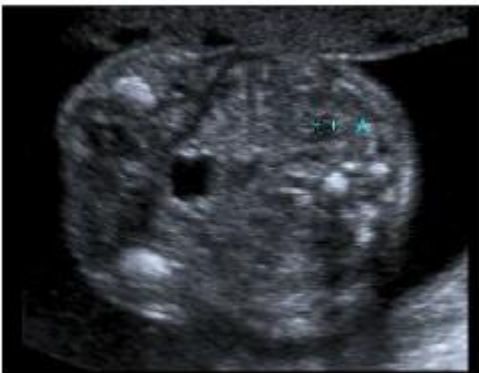Normal renal pelvis showing correct measurement



Example of renal pelvis dilatation



Example of incorrect measurement



Quality Assurance

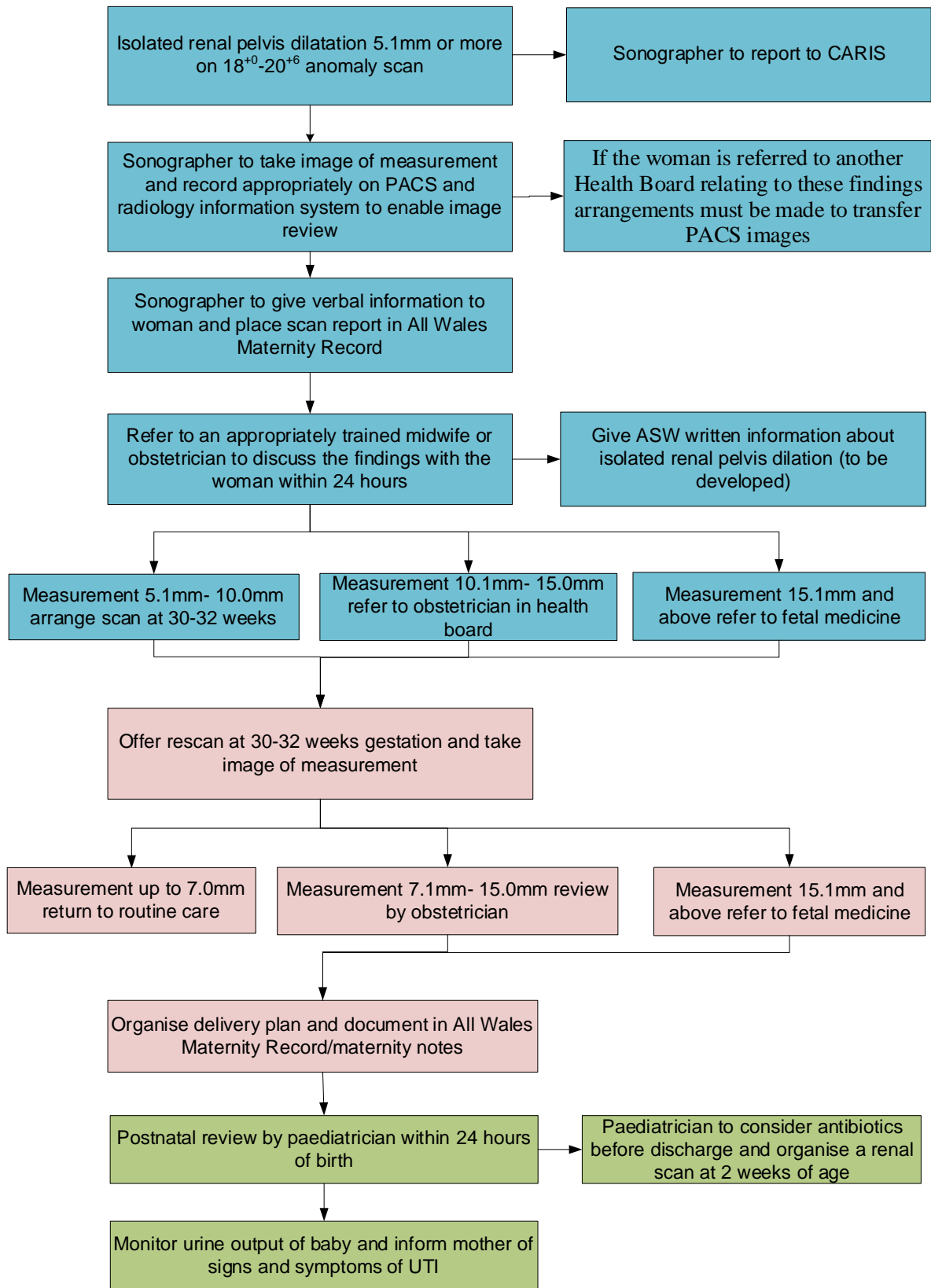
There must be an image from the anomaly scan stored digitally for review by the obstetrician or fetal medicine consultant. If the woman is referred to another health board relating to these findings arrangements must be made to transfer PACS images.

An audit of images should be arranged by the Health Board Ultrasound Obstetric Lead as recommended by the Society and College of Radiographers and the British Medical Ultrasound Society¹.

¹ SCoR and BMUS (2020) "Guidelines for Professional Ultrasound Practice" 5th ed. Society and College of Radiographers and British Medical Ultrasound Society.

Pathway renal pelvis dilatation

Colour Key: Anomaly Scan Third Trimester Postnatal Care



Isolated echogenic bowel

This pathway is for women where only echogenic bowel is identified on scan in the absence of any other identified structural abnormality (isolated).

Definition

Echogenic bowel is when loops of fetal bowel appear as bright as bone.

Possible Associated Clinical Conditions

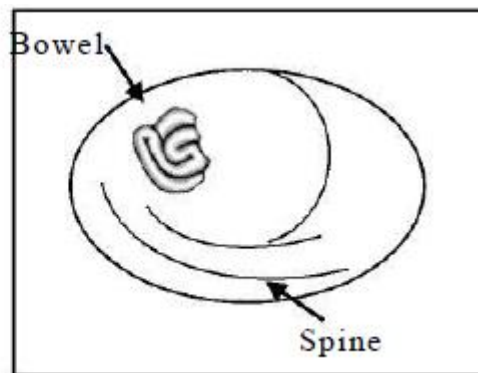
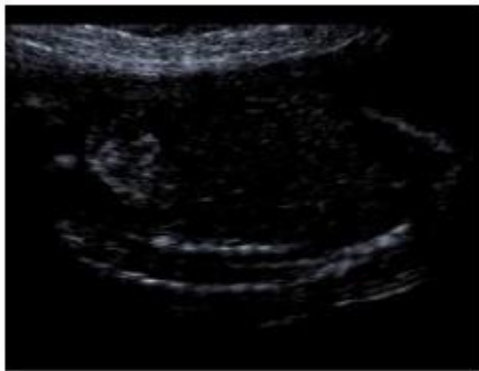
- Cytomegalovirus
- Cystic fibrosis
- Intrauterine growth restriction (IUGR)

This may also be caused by a placental haemorrhage at some time prior to the scan.

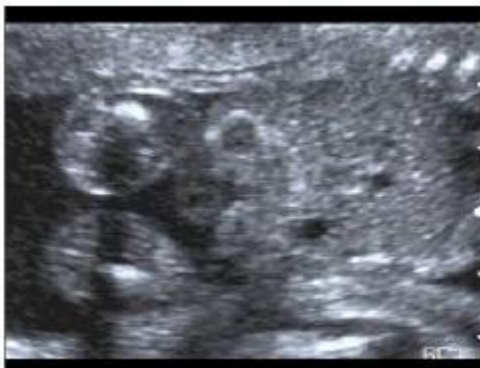Assessment

An area of increased echogenicity within the fetal abdomen that is as bright as bone. Single or multiple loops of bowel may be identified and it may be noted to be solid intraluminal echogenicity or occasionally echogenicity of the walls only (tram line).

Example of echogenic bowel



Example of incorrect image



The gain is too high in this image and needs to be reduced to show echogenic bowel

Internal Quality Assurance

There must be an image from the fetal anomaly ultrasound scan stored for review by the obstetrician or fetal medicine consultant. If the woman is referred to another health board relating to these findings the arrangements must be made for image transfer via PACS.

An audit of images should be arranged by the Health Board Ultrasound Obstetric Lead as recommended by the Society and College of Radiographers and the British Medical Ultrasound Society¹.

¹ SCoR and BMUS (2020) "Guidelines for Professional Ultrasound Practice" 5th ed. Society and College of Radiographers and British Medical Ultrasound Society.

Pathway for Isolated Echogenic Bowel

